

LATE-DIAGNOSED ASYMMETRIC BILATERAL TRAUMATIC HIP DISLOCATION: A CASE REPORT

LUXAÇÃO TRAUMÁTICA BILATERAL ASSIMÉTRICA DO QUADRIL COM DIAGNÓSTICO TARDIO: RELATO DE CASO

Article received on: 9/26/2025

Article accepted on: 12/26/2025

Roua Fahad Alghamdi*

*Collage of Medicine, Umm Al-Qura University, Makkah, Saudi Arabia
anoodalabbas@gmail.com

Waad Salem Almatrafi*

*Collage of Medicine, Umm Al-Qura University, Makkah, Saudi Arabia
anoodalabbas@gmail.com

Mohammed Saeed Alghamdi**

**King Abdullah Medical City, Makkah, Saudi Arabia
anoodalabbas@gmail.com

Ehab Elsherbiny***

***King Abdulaziz Hospital, Makkah, Saudi Arabia
anoodalabbas@gmail.com

Amani Omar Safdar*

*Collage of Medicine, Umm Al-Qura University, Makkah, Saudi Arabia
anoodalabbas@gmail.com


The authors declare that there is no conflict of interest

Abstract

Background: Bilateral traumatic hip dislocation is a rare and severe orthopedic injury that is typically associated with high-energy trauma. Asymmetric bilateral dislocations are particularly uncommon and may pose diagnostic challenges, especially when presentation or evaluation is delayed. Case Presentation: We report the case of a patient who sustained asymmetric bilateral traumatic hip dislocation following a high-energy road traffic accident. The patient presented with severe bilateral hip pain and inability to bear weight. Due to delayed diagnosis, orthopedic evaluation occurred more than nine hours after presentation. Imaging revealed anterior dislocation of the right hip and posterior dislocation of the left hip. Closed reduction of both hips was successfully performed under conscious sedation. On examination, the patient demonstrated left-sided foot drop consistent with sciatic nerve involvement. Post-reduction imaging confirmed concentric reduction of both hips. Conclusion: This case highlights the diagnostic challenges associated with asymmetric bilateral traumatic

Resumo

Antecedentes: A luxação traumática bilateral do quadril é uma lesão ortopédica rara e grave, normalmente associada a traumatismos de alta energia. As luxações bilaterais assimétricas são particularmente incomuns e podem representar desafios diagnósticos, especialmente quando a apresentação ou avaliação é tardia. Apresentação do caso: Relatamos o caso de um paciente que sofreu luxação traumática bilateral assimétrica do quadril após um acidente de trânsito de alta energia. O paciente apresentou dor bilateral intensa no quadril e incapacidade de suportar peso. Devido ao atraso no diagnóstico, a avaliação ortopédica ocorreu mais de nove horas após a apresentação. As imagens revelaram luxação anterior do quadril direito e luxação posterior do quadril esquerdo. A redução fechada de ambos os quadris foi realizada com sucesso sob sedação consciente. Ao exame, o paciente apresentou pé caído do lado esquerdo, consistente com envolvimento do nervo ciático. As imagens pós-redução confirmaram a redução concêntrica de ambos os quadris. Conclusão: Este caso destaca os



hip dislocation and underscores the importance of early recognition, comprehensive trauma assessment, and timely reduction to minimize complications such as avascular necrosis and neurological injury. Reporting such rare presentations contributes to increased clinical awareness and reinforces key principles in the management of traumatic hip dislocations.

Keywords: Hip Dislocation, Asymmetric, Bilateral, Trauma, Sciatic Nerve Injury, Delayed Diagnosis.

desafios diagnósticos associados à luxação traumática bilateral assimétrica do quadril e ressalta a importância do reconhecimento precoce, da avaliação abrangente do trauma e da redução oportuna para minimizar complicações como necrose avascular e lesão neurológica. Relatar apresentações tão raras contribui para aumentar a conscientização clínica e reforça os princípios-chave no tratamento de luxações traumáticas do quadril.

Palavras-chave: Luxação do quadril. Assimétrica. Bilateral. Trauma. Lesão do nervo ciático. Diagnóstico tardio.

1 INTRODUCTION

Traumatic hip dislocation is a serious orthopedic emergency that typically results from high-energy trauma, most commonly road traffic accidents (Thompson & Epstein, 1951; Hougaard & Thomsen, 1986). Although unilateral hip dislocation is well recognized, bilateral traumatic hip dislocation is rare and represents a small proportion of reported cases (Stewart & Milford, 1954). Asymmetric bilateral hip dislocation, in which each hip is displaced in a different direction, is an even more uncommon injury pattern and has been described mainly in isolated case reports (Buckwalter *et al.*, 2015).

The diagnosis of bilateral hip dislocation may be challenging, particularly in the setting of polytrauma, altered mental status, or delayed presentation (Hougaard & Thomsen, 1986). Clinical findings may be subtle or masked by associated injuries, increasing the risk of delayed recognition. Early reduction is widely emphasized in the literature to reduce the risk of complications such as avascular necrosis of the femoral head and neurological injury (Thompson & Epstein, 1951; Hougaard & Thomsen, 1986).

Asymmetric bilateral traumatic hip dislocations are infrequently reported, and the existing literature is largely limited to case reports and small case series (Buckwalter *et al.*, 2015). Reporting such cases remains important to highlight diagnostic challenges, unusual injury patterns, and key clinical considerations that may aid early recognition and appropriate management.

In this report, the researchers present a case of late-diagnosed asymmetric bilateral traumatic hip dislocation following a high-energy mechanism of injury, with an

associated neurological deficit. This case underscores the importance of maintaining a high index of suspicion for bilateral hip injuries in patients presenting after severe trauma.

2 CASE PRESENTATION

A 40-year-old male with no known pre-existing medical conditions was brought to the hospital by ambulance following a high-speed motor vehicle accident. On arrival, he was hemodynamically stable and reported severe pain in both hips and the right arm, in addition to multiple superficial wounds. The patient was agitated, which limited comprehensive assessment in accordance with Advanced Trauma Life Support (ATLS) principles during the initial evaluation. Initial assessment was therefore delayed, and further evaluation was performed after the patient consented to medical care more than nine hours after presentation.

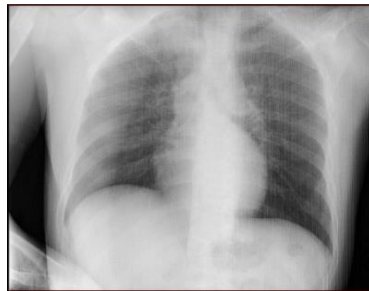During the primary survey, the patient's airway was intact, and a cervical collar was in place. Oxygen saturation was 100% on room air, with equal bilateral air entry, symmetrical chest movement, and no evidence of tracheal deviation. His heart rate was 94 beats per minute, and blood pressure was 157/100 mmHg. The patient was conscious, alert, and oriented, with a Glasgow Coma Scale score of 14/15. Examination of the head and neck revealed no lacerations or tenderness. Abdominal examination was unremarkable, with no tenderness or distension.

Examination of the upper limbs revealed an open fracture of the right proximal humerus with active bleeding; distal pulses were palpable, and sensory and motor functions were preserved. Examination of the lower limbs demonstrated asymmetric hip deformities: the left lower limb was adducted, flexed, internally rotated, and shortened, whereas the right hip and lower limb were extended, abducted, and externally rotated. Distal vascular examination of the left lower limb was intact; however, neurological examination revealed weakness manifested as foot drop.

Imaging following the ATLS protocol was delayed for several hours after the patient's presentation. A portable chest X-ray showed no abnormal findings (**Fig. 1**).

Figure 1

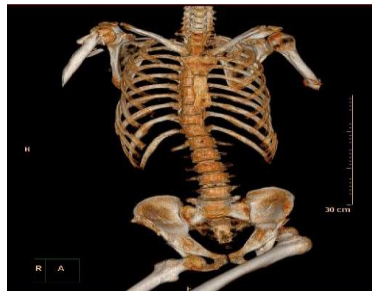Portable chest X-ray



In the emergency department, a portable pelvic X-ray was performed, revealing posterior dislocation of the left hip and anterior dislocation of the right hip. A subsequent pan-computed tomography scan confirmed both hip dislocations and identified an open fracture of the proximal humerus, with no evidence of other internal injuries (**Fig. 2**).

Figure 2

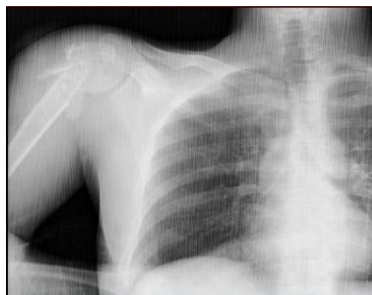Pan-computed tomography scan demonstrating bilateral hip dislocations.



Additionally, a right shoulder X-ray confirmed an open fracture of the right proximal humerus (**Fig. 3**).

Figure 3

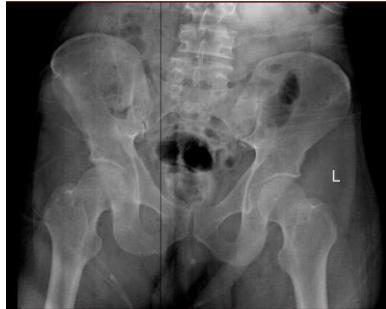Right shoulder X-ray demonstrating an open fracture of the proximal humerus.



The patient underwent conscious sedation for bilateral hip reduction, which was confirmed by a pelvic X-ray (**Fig. 4**).

Figure 4

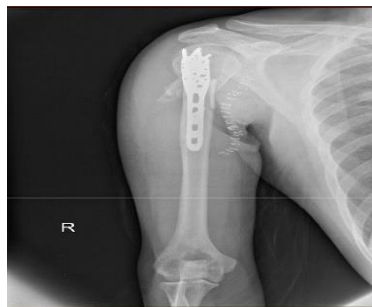Pelvic X-ray confirming reduction of both hip joints.



Following this, skin traction was applied to both hips. The open fracture of the right proximal humerus was treated with open reduction and internal fixation (ORIF) (**Fig. 5**).

Figure 5

Postoperative X-ray of the right shoulder following open reduction and internal fixation.



On subsequent clinical assessment, the patient was conscious, alert, and oriented, and remained hemodynamically stable with adequate pain control. The surgical wounds were clean and dry, and no additional complaints were reported. On follow-up, the patient demonstrated satisfactory recovery, mobilizing with a walker and achieving bilateral hip flexion of up to 90 degrees with full extension. Sutures were removed, and the wounds remained clean and dry.

3 DISCUSSION

Traumatic hip dislocation has been reported to occur predominantly in males, who account for approximately 81% of documented cases in the literature (Buckwalter *et al.*, 2015; Sah & Marsh, 2008). This male predominance has been attributed to anatomical and biomechanical differences between sexes. Females tend to exhibit increased femoral anteversion and anteverted acetabula, which may allow greater accommodation of axial femoral loads and potentially reduce the likelihood of traumatic dislocation (Harty, 1984).

Asymmetric bilateral traumatic hip dislocations result from substantial forces and are frequently associated with additional injuries. Concomitant fractures may involve the acetabulum or proximal femur, including the femoral head, neck, and peritrochanteric region (Buckwalter *et al.*, 2015; Meena *et al.*, 2021). Injuries outside the pelvic region are also commonly reported, such as fractures of the upper or lower extremities, as well as associated spinal, head, or abdominal trauma (Alshammari *et al.*, 2018; Levine *et al.*, 1999).

In the present case, the asymmetric bilateral hip dislocation was accompanied by an open fracture of the proximal humerus, reflecting the high-energy mechanism of injury. Similar patterns of associated injuries have been described in previously reported cases, underscoring the importance of a comprehensive trauma assessment in patients presenting with suspected bilateral hip dislocation (Buckwalter *et al.*, 2015; Uslu *et al.*, 2012). In severe trauma scenarios, patients may also present with hemodynamic instability or shock, further complicating early diagnosis and management (Levine *et al.*, 1999).

Several classification systems for traumatic hip dislocation are based on the final position of the femoral head relative to the acetabulum, categorizing dislocations as either posterior or anterior (Dawson-Amoah *et al.*, 2018; Obakponovwe *et al.*, 2011). Posterior traumatic hip dislocation represents the most common pattern, accounting for approximately 90% of reported cases (Brooks & Ribbans, 2000; Sah & Marsh, 2008). This injury mechanism is classically described as a “dashboard injury,” occurring when force is transmitted through a flexed knee with the hip in varying degrees of flexion, resulting in posterior displacement of the femoral head (Dawson-Amoah *et al.*, 2018; Obakponovwe *et al.*, 2011).

Anterior traumatic hip dislocation is considerably less common, comprising approximately 10% of cases (Brooks & Ribbans, 2000). It typically occurs when a hyperextension force is applied to an abducted lower limb, leading to anterior displacement of the femoral head from the acetabulum (Hani *et al.*, 2015; Sah & Marsh, 2008). Clinically, posterior hip dislocation is characterized by adduction and internal rotation of the affected limb, whereas anterior dislocation presents with abduction and external rotation—findings that were consistent with the clinical presentation observed in the current case (Dawson-Amoah *et al.*, 2018; Obakponovwe *et al.*, 2011).

Early recognition and prompt management of traumatic hip dislocation are critical to optimizing outcomes and minimizing complications. In patients with high-energy trauma, activation of standardized trauma protocols, including Advanced Trauma Life Support (ATLS), is essential to ensure airway protection, hemodynamic stabilization, and early identification of musculoskeletal injuries (Kool & Blickman, 2007). However, diagnosis may be delayed in certain circumstances, such as altered mental status, patient noncompliance, or the presence of multiple distracting injuries (Dawson-Amoah *et al.*, 2018).

When clinical findings raise suspicion of hip dislocation, an anteroposterior pelvic radiograph should be obtained during the secondary survey to confirm the diagnosis and to identify associated fractures that may contraindicate closed reduction, particularly femoral neck fractures (Brooks & Ribbans, 2000; Obakponovwe *et al.*, 2011). Computed tomography is recommended following reduction to assess concentricity of the joint and to identify associated acetabular fractures; however, it may be performed prior to reduction in patients with suspected abdominal or pelvic injuries (Brooks & Ribbans, 2000; Dawson-Amoah *et al.*, 2018).

In the present case, orthopedic evaluation and imaging were delayed due to patient noncompliance, resulting in a prolonged time to reduction. Similar delays have been described in previously reported cases and may complicate management despite adherence to standard trauma principles (Buckwalter *et al.*, 2015; Alshammari *et al.*, 2018). This highlights the importance of maintaining a high index of suspicion for bilateral hip injuries in patients presenting after severe trauma, even when initial evaluation is challenging.

Timely reduction of traumatic hip dislocation is widely regarded as a key factor in reducing the risk of complications, particularly avascular necrosis of the femoral head

and neurological injury. Most authors recommend reduction within six hours of injury when feasible, as delays beyond this period have been associated with increased rates of avascular necrosis and poorer functional outcomes (Dawson-Amoah *et al.*, 2018; Milenkovic *et al.*, 2022). Although some studies suggest that reduction within six to twelve hours may still be acceptable, earlier intervention remains preferable whenever possible (Buckwalter *et al.*, 2015; Milenkovic *et al.*, 2022).

Avascular necrosis following traumatic hip dislocation has been reported in approximately 6–27% of cases, with a higher incidence observed in posterior dislocations compared with anterior ones (Brav, 1962; Letournel & Judet, 1981). The initial clinical manifestation of avascular necrosis is often pain, and advanced imaging modalities such as magnetic resonance imaging or radionuclide bone scanning may be used for early detection during follow-up (Dawson-Amoah *et al.*, 2018).

Neurological injury represents another important complication, particularly involving the sciatic nerve, which courses posterior to the hip joint and is most commonly affected in posterior hip dislocations (Cornwall & Radomisli, 2000). Sciatic nerve injury has been reported in approximately 10% of posterior dislocations, with partial or complete recovery observed in 60–70% of patients (Cornwall & Radomisli, 2000; Dawson-Amoah *et al.*, 2018). In the present case, the patient developed foot drop consistent with sciatic nerve compression following delayed reduction, a finding that has been documented in similar cases of traumatic hip dislocation reported in the literature (Buckwalter *et al.*, 2015; Uslu *et al.*, 2012). The rarity of asymmetric bilateral traumatic hip dislocation, particularly when diagnosis is delayed, underscores the educational value of this case in highlighting key clinical, diagnostic, and management considerations.

4 CONCLUSION

Asymmetric bilateral traumatic hip dislocation is a rare and severe injury typically associated with high-energy trauma and a high risk of concomitant injuries. Early recognition and prompt reduction remain critical to minimizing complications, particularly avascular necrosis and neurological injury. This case illustrates the diagnostic challenges that may arise when presentation or evaluation is delayed, emphasizing the need for a high index of suspicion for bilateral hip dislocations in patients presenting after severe trauma.

Delayed diagnosis is not always attributable to system failure alone but may reflect the complex interaction between patient-related factors, distracting injuries, and asymmetric injury patterns that can obscure early clinical recognition despite adherence to trauma protocols. Comprehensive trauma assessment, appropriate imaging—including routine pelvic radiography—and timely reduction are essential for optimal outcomes. Reporting such rare presentations enhances clinical awareness and reinforces key principles in the diagnosis and management of traumatic hip dislocations.

REFERENCES

- Harty, M. (1984). The anatomy of the hip joint. In R. G. Tronzo (Ed.), *Surgery of the hip joint*. Springer. https://doi.org/10.1007/978-1-4612-5224-5_3
- Dawson-Amoah, K., Raszewski, J., Duplantier, N., & Waddell, B. S. (2018). Dislocation of the hip: A review of types, causes, and treatment. *Ochsner Journal*. <https://doi.org/10.31486/toj.17.0079>
- Hani, R., Kharmaz, M., & Berrada, M. S. (2015). Traumatic obturator dislocation of the hip joint: A case report and review of the literature. *The Pan African Medical Journal*. <https://doi.org/10.11604/pamj.2015.21.55.6392>
- Buckwalter, J., Westerlind, B., & Karam, M. (2015). Asymmetric bilateral hip dislocations: A case report and historical review of the literature. *The Iowa Orthopaedic Journal*. <https://pubmed.ncbi.nlm.nih.gov/26361448/>
- Sah, A. P., & Marsh, E. (2008). Traumatic simultaneous asymmetric hip dislocations and motor vehicle accidents. *Orthopedics*. <https://pubmed.ncbi.nlm.nih.gov/19292332/>
- Alshammari, A., Alanazi, B., Almogbil, I., & Alfayez, S. M. (2018). Asymmetric bilateral traumatic hip dislocation: A case report. *Annals of Medicine and Surgery*. <https://doi.org/10.1016/j.amsu.2018.06.008>
- Meena, U., Joshi, N., Behera, P., Meena, B., & Jain, S. (2021). Simultaneous asymmetrical bilateral hip dislocations – A report of three cases with different presentation and management. *Journal of Clinical Orthopaedics and Trauma*. <https://doi.org/10.1016/j.jcot.2021.101642>
- Levine, R. G., Kauffman, C. P., Reilly, M. C., & Behrens, F. F. (1999). ‘Floating pelvis’: A combination of bilateral hip dislocation with a lumbar ligamentous disruption. *The Journal of Bone and Joint Surgery*. British Volume <https://doi.org/10.1302/0301-620x.81b2.9350>
- Obakponovwe, O., Morell, D. J., Ahmad, M. A., Nunn, T., & Giannoudis, P. V. (2011). Traumatic hip dislocation. *Orthopaedics and Trauma*. <https://doi.org/10.1016/j.mporth.2011.04.006>

- Brooks, R. A., & Ribbans, W. J. (2000). Diagnosis and imaging studies of traumatic hip dislocations in the adult. *Clinical Orthopaedics and Related Research*. <https://doi.org/10.1097/00003086-200008000-00005>
- Kool, D. R., & Blickman, J. G. (2007). Advanced Trauma Life Support: ABCDE from a radiological point of view. *Emergency Radiology*. <https://doi.org/10.1007/s10140-007-0633-x>
- Milenkovic, S., Mitkovic, M., & Mitkovic, M. (2022). Avascular necrosis of the femoral head after traumatic posterior hip dislocation with and without acetabular fracture. *European Journal of Trauma and Emergency Surgery: Official Publication of the European Trauma Society*. <https://doi.org/10.1007/s00068-020-01495-x>
- Alonso, J. E., Volgas, D. A., Giordano, V., & Stannard, J. P. (2000). A review of the treatment of hip dislocations associated with acetabular fractures. *Clinical Orthopaedics and Related Research*. <https://doi.org/10.1097/00003086-200008000-00007>
- Brav, E. A. (1962). Traumatic dislocation of the hip: Army experience and results over a twelve-year period. *The Journal of Bone & Joint Surgery*. https://journals.lww.com/jbjsjournal/Abstract/1962/44060/Traumatic_Dislocation_of_the_Hip__Army_Experience.7.aspx
- Letournel, E., & Judet, R. (1981). *Fractures of the acetabulum*. Springer Berlin Heidelberg. <https://link.springer.com/book/10.1007/978-3-642-75435-7>
- Rodríguez-Merchán, E. C. (2000). Coxarthrosis after traumatic hip dislocation in the adult. *Clinical Orthopaedics and Related Research*. <https://pubmed.ncbi.nlm.nih.gov/10943189/>
- Nerubay, J. (1976). Traumatic anterior dislocation of hip joint with vascular damage. *Clinical Orthopaedics and Related Research*. <https://pubmed.ncbi.nlm.nih.gov/1277631/>
- Erb, R. E., Steele, J. R., Nance, E. P., Jr, & Edwards, J. R. (1995). Traumatic anterior dislocation of the hip: Spectrum of plain film and CT findings. *AJR. American Journal of Roentgenology*. <https://doi.org/10.2214/ajr.165.5.7572506>
- Cornwall, R., & Radomisli, T. E. (2000). Nerve injury in traumatic dislocation of the hip. *Clinical Orthopaedics and Related Research*. <https://doi.org/10.1097/00003086-200008000-00012>
- Uslu, M., Arican, M., Saritas, A., Buyukkaya, R., & Kandis, H. (2012). Combined bilateral asymmetric hip dislocation and anterior shoulder dislocation. *World Journal of Emergency Medicine*. <https://doi.org/10.5847/wjem.j.issn.1920-8642.2012.04.014>

Authors' Contribution

All authors contributed equally to the development of this article.

Data availability

All datasets relevant to this study's findings are fully available within the article.

How to cite this article (APA)

Alghamdi, R. F., Almatrafi, W. S., Alghamdi, M. S., Elsherbiny, E., & Safdar, A. O. (2026). LATE-DIAGNOSED ASYMMETRIC BILATERAL TRAUMATIC HIP DISLOCATION: A CASE REPORT. *Veredas Do Direito*, 23(3), e234613. <https://doi.org/10.18623/rvd.v23.n3.4613>